



## Original Research Article

# Histopathological study of appendectomy specimens: A two-year retrospective analysis

Anuradha Sinha<sup>a</sup>, Jatindra Deka<sup>b</sup>, Prabir Hazarika<sup>c</sup> and Jyoti Prakash Phukan<sup>d</sup>

a. Associate Professor, Department of Pathology, Deben Mahata Government Medical College, Purulia, West Bengal, Pin-723147, India.

b. Associate Professor, Department of Pathology, Tezpur Medical College, Tezpur, Assam, Pin-784153, India., India

c. Assistant Professor, Department of Pathology, Jorhat Medical College, Jorhat, Assam, India. Pin-785001, India

d. Associate Professor, Department of Pathology, Rampurhat Government Medical College, Rampurhat, West Bengal, Pin-731224, India.

**Article Information:** Received on 06-12-2021 Accepted on 29-12-2021 Available online 29/12/2022

## Abstract

**Introduction:** Appendectomy is one of the most common surgical procedures carried out in general surgery department and it is the most common cause acute abdomen in young adults. Routine histopathological (HP) examination of all resected appendix usually carried out in the Pathology department.

**Aims and Objective:** To find out the HP diagnosis of appendectomy specimens and to find out whether it correlates with preoperative clinical diagnosis.

**Materials and Methods:** We carried out retrospective analysis of all appendectomy specimens from January 2019 to December 2020. Total 121 cases were included in our study. Slides were reviewed, clinical data and HP diagnosis were retrieved from records of Pathology department. Data were compiled and analysed.

**Results:** Out of 121 cases, male constitute majority of cases (56.2%). Most of the patients had clinical diagnosis of acute appendicitis (70%) cases, and the most common HP diagnosis is also acute appendicitis (51.24%), followed by chronic/recurrent appendicitis (26.45%). Rare diagnosis of tuberculosis, carcinoid tumor, enterobius infestation and acute appendicitis due to taenia eggs also found (0.83% each).

**Conclusion:** Clinical diagnosis of acute appendicitis is not always correct; so routine HP examination of all appendectomy specimens should be done to arrive at exact diagnosis. HP examination also detects rare appendicular pathologies, which is essential for proper management.

**Keywords:** appendectomy, acute appendicitis, histopathological study

## 1. Introduction

Acute appendicitis is the most common non accidental surgical emergency worldwide [1]. Acute appendicitis is mostly treated with appendectomy and an appendectomy is a routinely performed surgical procedure worldwide. There is a rise of appendicitis cases in India especially among urban population due to acceptance of western pattern of diet [2]. Histological examination revealed that about 20% of patients who have undergone appendectomy do not have acute appendicitis [3]. This is more commonly seen in females.

Presenting symptoms of acute appendicitis includes pain in the right iliac fossa, vomiting, fever, tenderness, guarding and rebound tenderness. Appendectomy is the preferred mode of treatment in these cases; however, misdiagnosis is not uncommon. Very commonly, appendicitis is misdiagnosed in non-pregnant women of child-bearing age. Wrong diagnosis leads to surgical removal of normal un-inflamed appendix in many cases.[4].

Acute appendicitis is uncommon in infants, and it reaches a peak incidence in teens and early twenties [5]. In young adults, the ratio of acute appendicitis among males and females is 3:2 and with increasing age, the greater incidence among males decreases. The most common cause of appendicitis is obstruction to the lumen; causes include faecolith, lymphoid hyperplasia and foreign bodies [6]. There are also some uncommon factors and includes parasitic infestations like enterobius, ascariasis, tuberculosis or a tumor as

\*Corresponding author: Dr. Jyoti Prakash Phukan, Department of Pathology, Rampurhat Government Medical College, Rampurhat, West Bengal, Pin-731224, India. E-mail: [drjyotiphukan@yahoo.co.in](mailto:drjyotiphukan@yahoo.co.in)  
doi: <http://doi.org/10.54618/IJMAHS.2021123>

This is an open-access article, which permits the use and distribution of article provided that original author and source are credited.

carcinoid, primary or secondary adenocarcinoma, lymphoma, gastrointestinal stromal tumor etc [7].

The gold standard method for confirmation of acute appendicitis is the HP examination of resected specimen and it also rule out any underlying uncommon pathology. So, the study was undertaken with an aim to determine the histopathological diagnosis of all resected appendix, and to find out whether the preoperative clinical diagnosis correlates with final HP diagnosis.

### 2. Material and Methods

This 2-years retrospective study was conducted in the department of Pathology of a medical teaching institute of north-eastern India. All patients regardless of age who went appendectomy for any reason and whose histopathological examinations were done; included in the study.

Study period of the study was January 2019 to December 2020. Total 121 appendectomy cases were included in the study. In every case, clinical and demographic data were recorded. HP slides were retrieved from the archive and HP reports were collected from records.

The reports were collected and data were analysed regarding incidences of age, sex, and other co-incidental findings. The final histopathological reports were correlated with the pre-operative clinical diagnosis.

### 3. Results

During our study period, total 121 cases of appendectomy were found. Among the cases, male to female ratio is 1.3:1 [Table 1]. The youngest patient is 7 years old, while the oldest patient is 69 years old female, both were presented with clinical features of acute appendicitis. Highest number of patients were seen in 20-29 years age group (32 cases) [Table 1].

**Table 1:** Age and gender distribution of appendectomy cases

Age (in years)	Males	Females	Total
0-9	1	0	1
10-19	19	8	27
20-29	27	5	32
30-39	11	16	27
40-49	5	13	18
50-59	5	8	13
60-69	0	3	3
70 and above	0	0	0
Total	68(56.2%)	53(43.8%)	121(100%)

Most of the patients (97) presented with clinical diagnosis of acute appendicitis with history of right iliac fossa pain with fever and with or without vomiting [Table 2]. However, most of them found to be having

acute appendicitis (52 cases, 53.6%), followed by chronic/recurrent appendicitis (22 cases, 22.7%) and acute appendicitis with peri appendicitis (17 cases,17.5%) in histopathological examination. The final HP diagnosis of all appendectomy cases is summarised in Table 3.

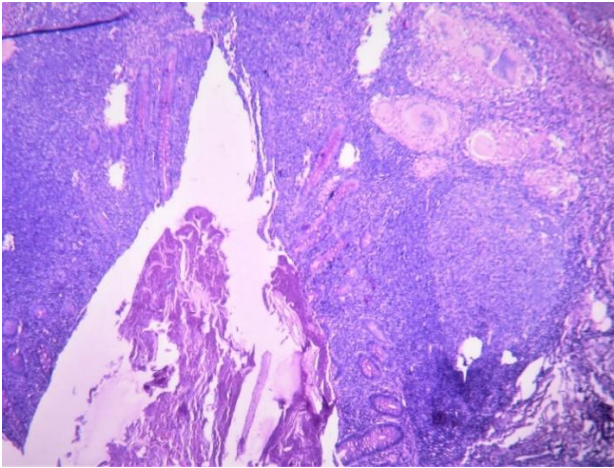
**Table 2:** Showing final histopathological diagnosis of patients with pre-operative clinical diagnosis of acute appendicitis.

Clinical diagnosis	Histopathological diagnosis	No of cases	%
Acute appendicitis 97 cases	Acute appendicitis	52	53.6
	Acute appendicitis with periappendicitis	17	17.5
	Acute gangrenous appendicitis	2	2.0
	Acute appendicitis with perforation	2	2.0
	Chronic/recurrent appendicitis	22	22.7
	Tinea eggs	1	1.0
	Enterobius vermicularis	1	1.0
	Total	97	100.0

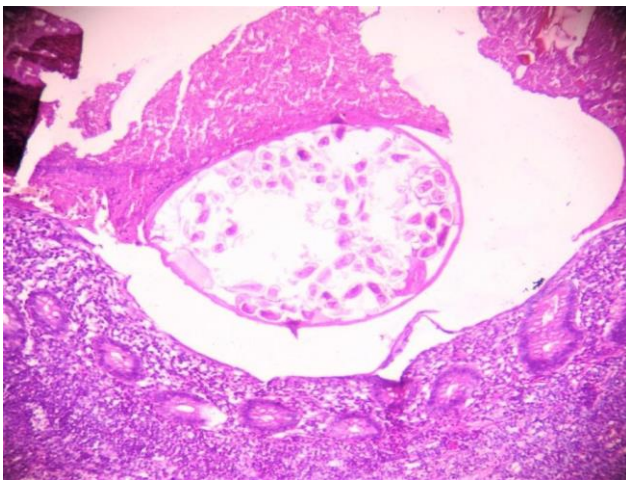
**Table 3:** Histopathological diagnosis of appendectomy specimens.

Histopathological diagnosis	No of cases (n= 121)	%
Acute appendicitis	62	51.24
Acute appendicitis with periappendicitis	19	15.7
Chronic/recurrent appendicitis	32	26.45
Acute gangrenous appendicitis	2	1.65
Acute appendicitis with perforation	2	1.65
Tuberculous appendicitis	1	0.83
Enterobius vermicularis	1	0.83
Acute appendicitis due to eggs of taenia species	1	0.83
Carcinoid tumor	1	0.83
Total	121	100

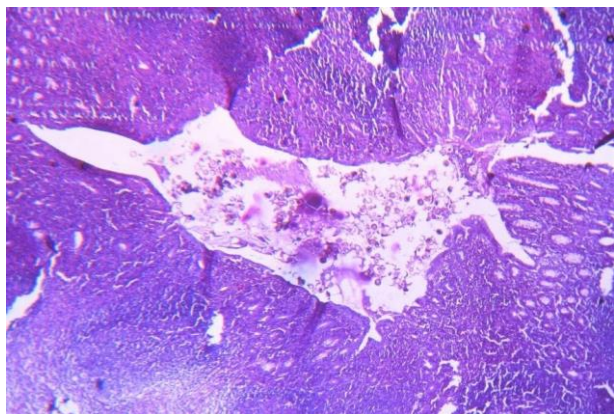
Acute appendicitis is most common histological diagnosis in 62 cases (51.24%), followed by chronic appendicitis (32 case, 26.45%). Rare HP diagnosis such as tuberculosis of appendix (Figure 1), enterobius infestation (Figure 2), appendicitis due to tinea eggs (Figure 3) also found with 1 each.



**Figure 1:** Photomicrograph showing histopathological features of tuberculosis of appendix having epithelioid granuloma marked by caseous necrosis and Langhans' giant cells (H&E,  $\times 400$ )



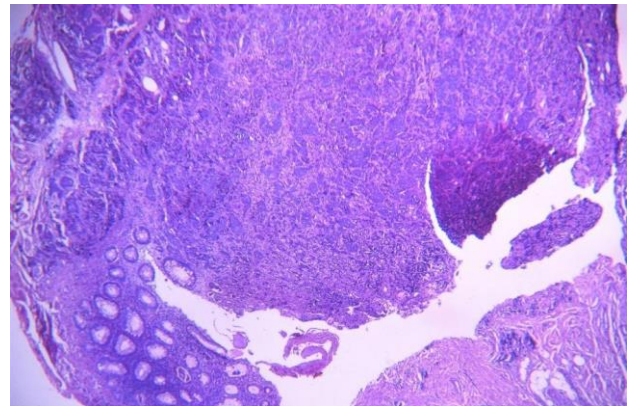
**Figure 2:** Photomicrograph showing enterobius vermicularis in appendicular lumen (H&E, 400)



**Figure 3:** Photomicrograph showing histopathological features of acute appendicitis due to presence of numerous eggs of Tinea species. (H&E,  $\times 100$ )

The only neoplastic condition, we have encountered, was carcinoid tumor of appendix (Figure 4). All these cases were diagnosed preoperatively as acute or

recurrent appendicitis. Therefore, the HP diagnosis of these cases had considerable impact on patient management.



**Figure 4:** Photomicrograph showing carcinoid tumor of appendix, having monomorphic cell population arranged in nests and insular pattern involving wall of the appendix. (H&E,  $\times 100$ )

#### 4. Discussion

Acute appendicitis is one of the most common surgical emergencies especially in the Western world [6]. Recent studies suggest that the case of acute appendicitis is on rise in developed countries probably due to adaptation of Western diet. So, in India, emergency appendectomy cases are rising. Various factors may have role in the development of acute appendicitis such as race, age, sex, geographic region, socio-economic status, dietary habits, and hygiene [2].

Although vermiform appendix is considered to be a vestigial organ, it is one of most common organs inflicted by pathology. The clinical importance of appendix lies on its propensity for inflammation, which cause a clinical syndrome called acute appendicitis [5]. The clinical presentation of acute appendicitis is sudden onset lower abdominal pain, which later localised to McBurney's point, nausea, vomiting and fever [4]. Appendectomy is usually done for the management of acute appendicitis. An untreated case of acute appendicitis may lead to perforation of appendix which may lead to generalised peritonitis. Again, if the symptoms are tolerated, there may be formation of appendicular mass, which is a protective phenomenon. However, clinical diagnosis is not always correct. Misdiagnosis is common especially in non-pregnant women of child-bearing age. Till date, no reliable laboratory test or examination is sensitive and specific enough to diagnose appendicitis correctly. About 7% of population have life-time risk of developing appendicitis with maximum cases occur between 10 to 30 years age group [7]. The importance of histopathological examination of surgically resected appendix lies on confirmation of clinical diagnosis of acute appendicitis and in the diagnosis of uncommon pathologies that can be found on HP examination which are not evident clinically and intraoperatively, which

may have important implications in patient's management [8].

Our study revealed that apart from acute appendicitis, many other pathologies can affect appendix. We found that acute appendicitis was more common in 20-29 years followed by 30-39 years age group and females were more commonly affected than males. The age groups affected by acute appendicitis and male preponderance are similar, as found in various other studies such as Sinha et al, Ojo et. al., Shreshtha et. al. and Kulkarni et al [5,9-11]. Most of patients in our study presented with clinical features of acute appendicitis, however a good number of patients also presented with features of recurrent appendicitis with history of on-and-off pain in the right iliac fossa. In other studies, done by Sujatha et al and Edino et al., found that majority of the patients presented with abdominal pain which is similar to our findings [6,12].

Unequivocal obstruction in the form of faecolith is a common finding in patients with appendicitis. Intestinal parasites, seeds, food residue, barium from radiographic studies and the neoplasm of caecum can also causes obstruction [11].

Out of 121 appendectomy cases, only 1 case was found to have neoplastic condition (0.83%) and other having non-neoplastic condition (99.17%). Blair et al reported 4% neoplastic conditions in appendectomy specimens [13]. The small percentage of neoplastic lesion in our study is probably due to small number of cases. Due to Covid-19 pandemic, except emergency operative procedures, routine surgical operations were not done, which contributes for small sample size in our study.

In our study, majority of HP diagnosis was acute appendicitis (53.6%) followed by chronic appendicitis (22.7%). This finding correlates well with other studies done by Sujatha et al and Blair et al [6,13]. We have also encountered a good number of cases of acute appendicitis with peri appendicitis (17.5%). Other findings include acute gangrenous appendicitis and acute appendicitis with perforation 2 cases each (2% of each). This finding is like the study done by Sinha et al [5]. These findings reflect delay in seeking medical help. Perforation of appendix can be life threatening as it can leads to generalised peritonitis. However, none of our patient developed such complications and recovered well.

We have encountered 1 case (0.83%) of tuberculous inflammation of appendix, which is not a common finding. It was an incidental finding as it was not clinically suspected. Tuberculosis of appendix can be primary or secondary, where incidence of primary tuberculosis of appendix has been reported to be 0.1-0.6% [14]. Our case was a case of primary tuberculosis. The lesion can be identified by presence of granuloma consisting of areas of caseous necrosis and Langhans' giant cells with no other foci of tuberculosis elsewhere in the body.

One case of enterobius vermicularis infestation was noted in our study. In was clinically diagnosed as

chronic and recurrent appendicitis. *E. Vermicularis* is usually associated with chronic inflammatory changes rather than acute inflammation [15]. Kulkarni et al found 14 cases (3.3%) of *E. Vermicularis* infestation in the appendix and all were associated with chronic inflammation [11]. They also found that 92.85% of *E. Vermicularis* parasites to be luminal. In our only case, the parasite was luminal; not attached to the mucosa.

We have found another interesting case of acute appendicitis due to eggs of taenia species. Adult worms of *Taenia solium* and *Taenia saginata* harbored in human intestine, who acts as definitive host. Presence of taenia eggs is quite rare. Silva et al [16] performed a retrospective study, comprising of 1,600 appendectomies over a period of 10 years and found only one case of appendicular taeniasis. Morphologically the eggs of *T. solium* and *T. saginata* are identical and can't be distinguished [17]. They are spherical and measure 30-40 µm in diameter.

The only neoplastic lesion that we have encountered is carcinoid tumour. Only a single case (0.83%) of carcinoid tumour was found. This finding is like study done by Jones et al who found 13 (1.06%) cases of carcinoid tumour among 1225 cases studied [8]. Again, Hof et al., found only 07 (0.47%) cases of carcinoid tumour in their study comprising of 1485 number of appendectomies [18]. Carcinoids are the most common tumour found in the appendix and grossly, it is small, firm and well circumscribed yellow brown lesion [19]. The patients usually present with features of appendicitis because the tumours may lead to luminal obstruction [20]. They rarely presented with neuroendocrine symptoms, which includes flushing, diarrhoea and cardiac disease [21].

## 5. Conclusions

Majority of acute appendicitis is found in 2<sup>nd</sup> and 3<sup>rd</sup> decades and males are slightly more affected. The clinical diagnosis is not always correct. Again, some of rare pathologies can be easily missed preoperatively. Hence, it is important to do histopathological examination of every surgically removed appendix to confirm the clinical diagnosis and to rule out any underlying uncommon pathology. The uncommon diagnoses are essential for proper management which would not be possible unless histopathological examination done.

## Competing interest

The authors declare that there are no conflicts of interest.

## References

- [1]. Marudanayagam R, Williams GT, Rees BI. Review of the pathological results of 2660 appendectomy specimens. *J Gastroenterol* 2006; 41:745-749.
- [2]. Oguntola AS, Adeoti ML, Oyemolade TA. Appendicitis: Trends in incidence, age, sex and seasonal variations in South-western Nigeria. *Ann Afr Med* 2010; 9:213-217.

- [3]. Rothrock SG, Green SM, Dobson M, Colucciello SA, Simmons CM. Misdiagnosis of appendicitis in nonpregnant women of childbearing age. *J Emerg Med* 1995; 13:1-8.
- [4]. Myageri A, Agnihotri AD, Chauhan LDS. Clinicopathologic study of appendix specimens-a two-year retrospective study at a tertiary care centre. *Nat J Lab Med* 2019;8:PO05-10.
- [5]. Sinha RTK, Dey A. A retrospective study of histopathological features of appendectomy specimens-what all can expect? *J Med Sci Health* 2016; 2:6-12.
- [6]. Sujatha R, Anushree CN, Singh N. Histopathological spectrum of appendectomy specimens- A prospective study. *Ind J Pathol Oncol* 2017;4:638-642.
- [7]. O'Connell PR. The vermiform appendix. In: Russell RC, Williams NS, Bulstrode CJ. Editors. *Bailey and Love's Short Practice of Surgery*. 26<sup>th</sup> ed. London: Arnold Hodder;2010. p.1203-1218.
- [8]. Jones AE, Phillips AW, Jarvis JR, Sargen K. The value of routine histopathological examination of appendectomy specimens. *BMC Surg* 2007; 7:17.
- [9]. Ojo OS, Udeh SC, Odesanmi WO. Review of the histopathological findings in appendices removed for acute appendicitis in Nigerians. *J R Coll Surg Edind* 1991; 36:245-248.
- [10]. Shreshtha R, Ranabhat SR, Tiwari M. Histopathological analysis of appendectomy specimens. *J Pathol Nepal* 2012; 2:215-219.
- [11]. Kulkarni MP, Sulhyan KR, Barodawala SM, Yadav DH. Histopathological study of lesions of the appendix. *Int J Health Sci Res* 2017; 7:90-95.
- [12]. Edino ST, Mohammed AZ, Ochicha O, Anumah M. Appendicitis in Kano, Nigeria: a 5 years review of pattern, morbidity and mortality. *Ann Afr Med* 2004; 3:38-41.
- [13]. Blair NP, Bugis SP, Turner LJ, Macleod MM. Review of the pathologic diagnosis of 2216 appendectomy specimens. *Am J Surg* 1993; 165:618-620.
- [14]. Rai SP, Shukla A, Kashyap M, Dahiya RK. Isolated tuberculosis of the appendix. *Ind J Tuberc* 2004; 51:239-240.
- [15]. Mowlavi GH, Massound J, Mobedi I, Rezaian M, Mohammadi SS, Mostoufi NE *et al*. Enterobius vermicularis: a controversial cause of appendicitis. *Iran J Public Health* 2004; 33:27-31.
- [16]. Silva DF, Silva RJ, Silva MG, Sartorelli AC, Takegawa BK, Rodrigues MA. Parasitic infection of the appendix and its possible relationship to acute appendicitis. *Arq Gastroenterol*. 2008; 45:166-168.
- [17]. Chakrabarti I, Gangopadhyay M, Bandopadhyay A, Das NK. A rare case of gangrenous appendicitis by eggs of Taenia species. *J Parasit Dis* 2014;38:135-137.
- [18]. In't Hof KH, Van Der Wal HC, Kazemier G, Lange JF. Carcinoid tumor of appendix. An analysis of 1485 consecutive emergency appendectomies. *J Gastrointest Surg* 2008; 12:1436-1438.
- [19]. Matthyssens LE, Ziol M, Barrat C, Champault GG. Routine surgical pathology in general surgery. *Br J Surg* 2006; 93:362-368.
- [20]. Gu Y, Wang N, Xu H. Carcinoid tumor of the appendix: a case report. *Oncol Lett* 2015; 9:2401-2403.
- [21]. Markgraf WH, Dunn TM. Appendiceal carcinoid with carcinoid syndrome. *Am J Surg*. 1964; 107:730-732.